

# THE PATIENT PRESENTS WITH



- |                              |    |  |     |
|------------------------------|----|--|-----|
| 1. Chest pain                | 3  | 12. Abdominal pain                             | 67  |
| 2. Shortness of breath       | 9  | 13. Polyuria and polydipsia                    | 73  |
| 3. Palpitations              | 15 | 14. Haematuria and proteinuria                 | 79  |
| 4. Heart murmurs             | 21 | 15. Hypertension                               | 85  |
| 5. Cough and haemoptysis     | 29 | 16. Headache and facial pain                   | 89  |
| 6. Pyrexia of unknown origin | 35 | 17. Joint disease                              | 95  |
| 7. Dyspepsia                 | 39 | 18. Skin diseases                              | 101 |
| 8. Haematemesis and melaena  | 43 | 19. Loss of consciousness                      | 107 |
| 9. Change in bowel habit     | 49 | 20. Confusional states                         | 115 |
| 10. Weight loss              | 55 | 21. Acute neurological deficit                 | 121 |
| 11. Jaundice                 | 61 | 22. Lymphadenopathy and<br>splenomegaly        | 127 |
|                              |    | 23. Sensory and motor neurological<br>deficits | 133 |
|                              |    | 24. Bruising and bleeding                      | 141 |
|                              |    | 25. Vertigo and dizziness                      | 147 |
|                              |    | 26. Anaemia                                    | 153 |



# Chest pain

1



## Objectives

In this chapter you will learn to:

- Understand the causes of chest pain.
- Have a systematic approach to assessing a patient presenting with chest pain.
- Understand the sequence of investigations in a patient with chest pain.

## INTRODUCTION

Chest pain is a common cause for both referral and admission to hospital. It has many possible aetiologies that need to be elucidated. Taking a clear history is essential in making the correct diagnosis.

- Rib fracture.
- Shingles (herpes zoster): pain precedes rash.
- Costochondritis (Tietze's syndrome).

## Atypical presentations

The differential diagnosis in atypical presentations (or in any of the above) includes anxiety and referred pain from vertebral collapse causing nerve root irritation or intra-abdominal pathology (e.g. pancreatitis, peptic ulcer or biliary tree disorders).

## DIFFERENTIAL DIAGNOSIS OF CHEST PAIN

### Pleuritic chest pain

This is a sharp pain that is worse on deep inspiration, coughing or movement. The differential diagnosis includes the following:

- Pneumothorax.
- Pneumonia.
- Pulmonary embolus.
- Pericarditis: retrosternal.

### Central chest pain

The differential diagnosis of central pain includes the following:

- Angina: crushing/tightness.
- Myocardial infarction: angina-like but more severe, long-lasting and with associated symptoms.
- Dissecting aortic aneurysm: tearing interscapular pain.
- Oesophagitis: burning.
- Oesophageal spasm.

### Chest wall tenderness

The differential diagnosis of chest wall tenderness includes the following:

## HISTORY IN THE PATIENT WITH CHEST PAIN

A careful history of the chest pain will generally be suggestive of the likely underlying problem. The focus should then turn to any associated symptoms and risk factors.

## What type of chest pain does the patient have?

### Onset and progression of pain

Cardiac ischaemic pain typically builds up over a few minutes and may be brought on by exercise, emotion or cold weather. In angina, the pain resolves on resting or with nitrate (GTN) usage. It is often reproducible with consistent effort. In unstable angina, the pain may come on at rest or be of increasing frequency or severity. In myocardial infarction (MI), the pain is severe, often associated with systemic symptoms such as nausea, vomiting and sweating, lasts for at least 30 minutes and is not usually fully relieved by GTN. Spontaneous pneumothorax and pulmonary embolism usually cause sudden onset of pleuritic

3

## Chest pain

pain and dyspnoea (the patient often remembers exactly what they were doing at the time).

Always be aware of the patient with chronic stable angina whose symptoms are more frequent or occurring at rest. This is a medical emergency.

### Site and radiation of pain

Cardiac ischaemia and pericarditis cause retrosternal pain. With ischaemia, the pain is tight and 'crushing', often radiating to the neck, jaw or arms. Pericarditis is pleuritic and may be worse on lying flat but relieved by sitting forward. A dissecting aortic aneurysm causes tearing pain radiating through to the back. Pulmonary disease may cause unilateral pain, which the patient can often localize specifically. Oesophageal disease can also cause retrosternal pain and may mimic cardiac pain. Referred pain from vertebral collapse or shingles will follow a dermatomal pattern.

### Nature of pain

The precise nature of the pain gives important clues as to the underlying diagnosis (see above).

### Are there any associated symptoms?

Important associated symptoms include:

- Dyspnoea: pulmonary embolism, pneumonia, pneumothorax, pulmonary oedema in cardiac ischaemia, hyperventilation in anxiety.
- Cough: purulent sputum in pneumonia, haemoptysis in pulmonary embolism, frothy pink sputum in pulmonary oedema.
- Rigors: pneumonia (particularly lobar pneumococcal pneumonia).
- Calf swelling: has a pulmonary embolism (PE) arisen from deep vein thrombosis?
- Palpitations: arrhythmia, e.g. new onset atrial fibrillation, can cause angina or result from cardiac ischaemia, PE or pneumonia.
- Clamminess, nausea, vomiting and sweating are features of myocardial infarction or massive pulmonary embolism.

### Are risk factors present?

Important risk factors include:

- Ischaemic heart disease: smoking, family history, hypercholesterolaemia, hypertension, diabetes.

- PE: recent travel, immobility, or surgery, family history, pregnancy, malignancy.
- Pneumothorax: spontaneous (young, thin men), trauma, emphysema, asthma, malignancy.

## EXAMINING THE PATIENT WITH CHEST PAIN

The examination should focus on determining the cause of the pain then looking for risk factors and consequences of the underlying problem. A schematic guide to examining the patient with chest pain is given in Fig. 1.1.

### What is the cause of the pain?

Pay particular attention to:

- Pulse: tachycardia/bradycardia or arrhythmia.
- Blood pressure: discrepancy between left and right arms in aortic dissection (the pulse volumes may also be unequal).
- Chest wall tenderness: rib fracture, costochondritis, anxiety, shingles.
- Chest examination: pneumothorax, consolidation, pleural rub, pulmonary oedema.
- Cardiac examination: rub (pericarditis), murmur of aortic regurgitation in aortic dissection.

### Are there risk factors?

The following risk factors may be present:

- Abnormal lipids: xanthelasma, tendon xanthoma.
- Tar-stained fingers: predisposition to ischaemic heart disease.
- Hot, oedematous, tender calf suggesting deep vein thrombosis.
- Hypertension, ischaemic heart disease, features of Marfan's syndrome or of diabetes.

### What are the complications?

Complications may include:

- Pulse: arrhythmia, tachycardia/bradycardia.
- Blood pressure: shock in tension pneumothorax, massive pulmonary embolism, MI.
- Cardiac failure: pulmonary oedema and third heart sound.
- Murmurs: acute mitral regurgitation and ventricular septal defect after MI.

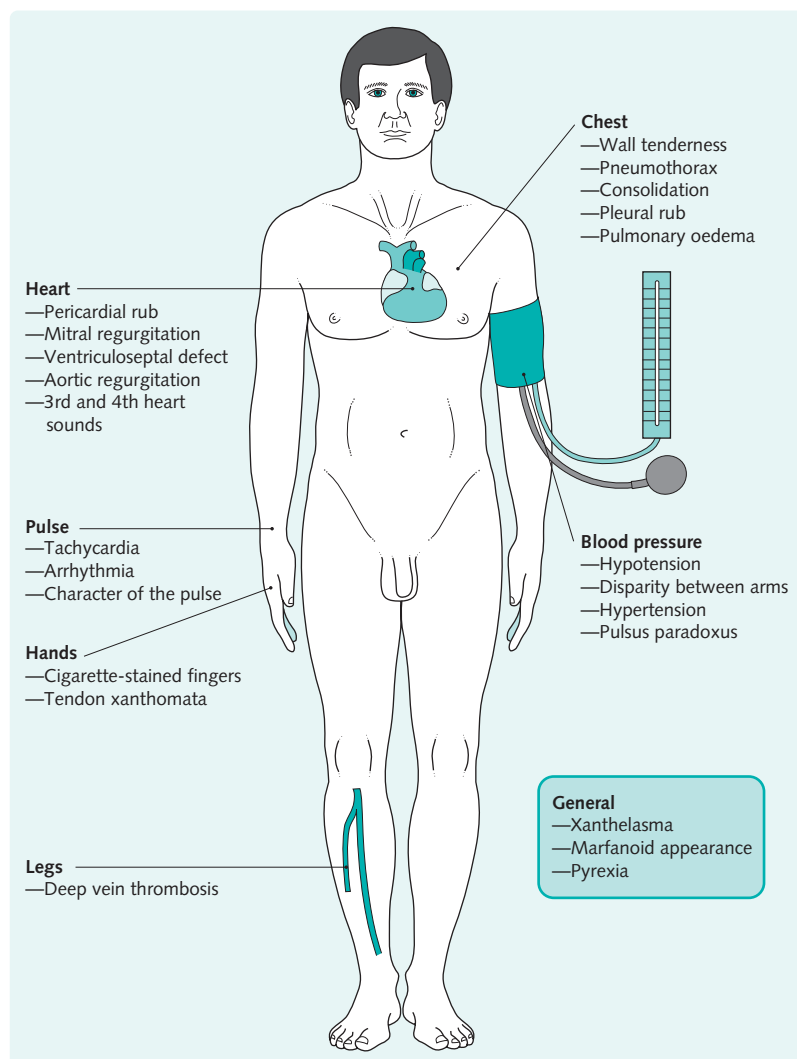


Fig. 1.1 Examining the patient with chest pain.

## INVESTIGATING THE PATIENT WITH CHEST PAIN

All patients with chest pain should have an electrocardiogram (ECG) and chest radiograph (CXR). Further investigation will be directed by findings in these tests in conjunction with the history and clinical examination. An algorithm for the investigation of the patient with chest pain is given in Fig. 1.2.

### Blood tests

Patients will have a full blood count, urea and electrolytes and glucose performed as routine. Other tests may include cardiac enzymes, Troponin I or T

(see Chapter 40) at 6–12 hours after symptom onset, inflammatory markers or D-dimers as guided by history and examination. Aspartate transaminase and lactate dehydrogenase are now largely redundant in acute ischaemic chest pain.



While cardiac enzymes have been largely replaced by troponin measurements, they remain useful after MI to assess reinfarction, as troponins remain raised for 2 weeks and creatine kinase returns to normal after 2–3 days.

Chest pain

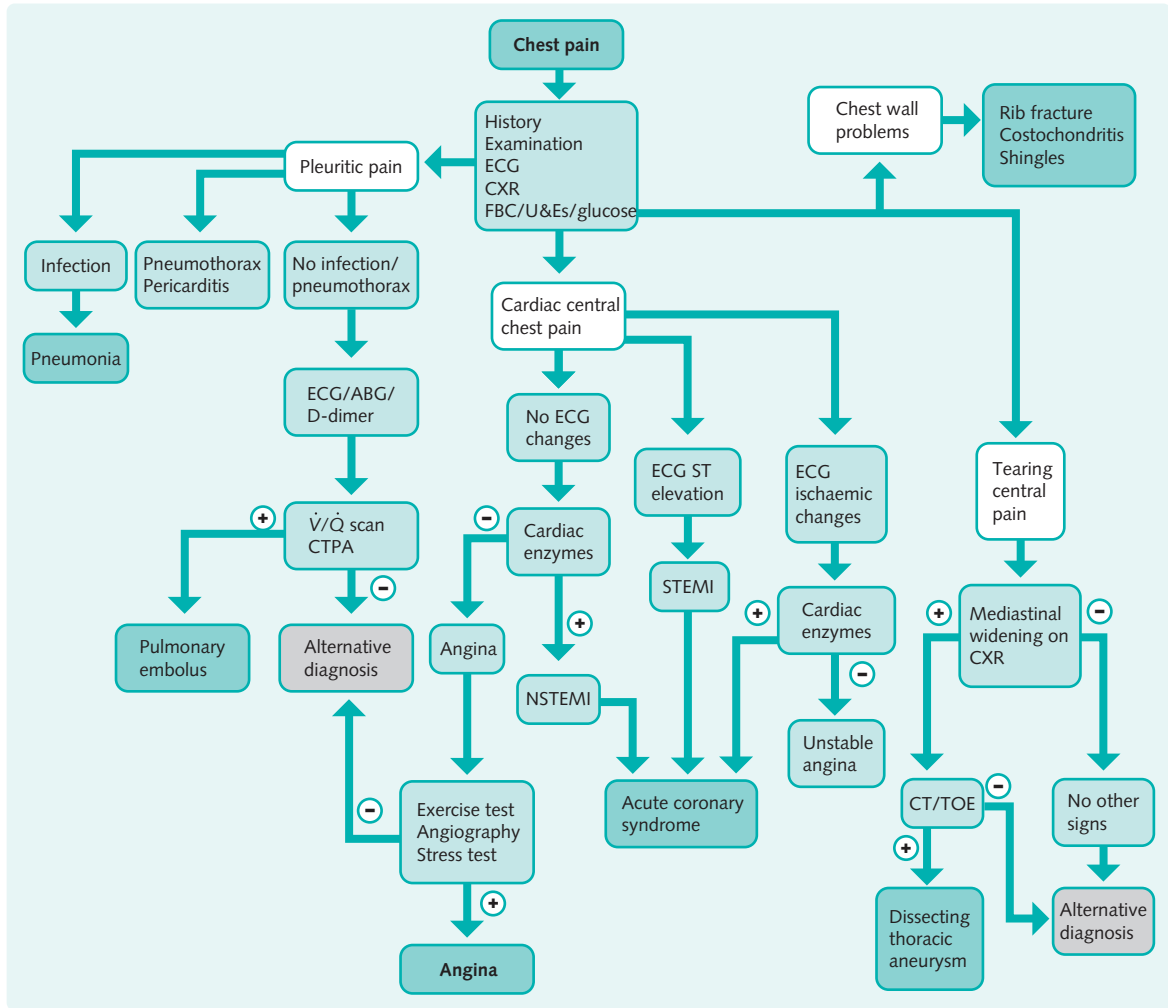


Fig. 1.2 Algorithm for the investigation of the patient with chest pain. (CT, computed tomography; CTPA, computed tomography pulmonary angiogram; CXR, chest X-ray; ECG, electrocardiogram; FBC, full blood count; NSTEMI, non-STEMI; STEMI, ST-segment elevation myocardial infarction; TOE, transoesophageal echocardiography; U&Es, urea and electrolytes; V/Q scan, ventilation-perfusion scan.)

### Electrocardiogram

New-onset left bundle branch block, T wave changes, ST depression and elevation (Fig. 1.3) on ECG are suggestive of an acute coronary syndrome. It is vital to recognize those patients who would benefit from thrombolysis or angioplasty as soon as possible. The management of myocardial infarction with and without ST segment elevation is discussed later (see Chapter 27). Changes suggestive of PE are shown in Fig. 1.4. Arrhythmia may also be detected on ECG.

Serial or continuous ECGs may be needed as all the disease processes can be dynamic.



Patients with chest pain are often very scared. Their fears can be allayed by explaining the sequence of investigations, the most likely diagnosis and treatment options.

Fig. 1.3 Causes of ST elevation on ECG

Cause	Distribution of ST elevation
Myocardial infarction	Inferior aVF, II, III Anteroseptal V <sub>1-4</sub> Lateral I, aVL, V <sub>4-6</sub>
Pericarditis	Across all leads (saddle-shaped ST change)
Prinzmetal's angina	Leads of affected coronary artery (spasm)
Aortic dissection	Only if coronary artery involved
Left ventricular aneurysm	Persistent elevation for 6 months following infarct

Fig. 1.4 ECG changes associated with pulmonary embolus

- Sinus tachycardia
- Atrial arrhythmia, e.g. atrial fibrillation
- Right heart strain
- Right axis deviation
- Right bundle branch block
- S<sub>1</sub> Q<sub>3</sub> T<sub>3</sub>, i.e. deep S wave in I, Q wave in III, T wave inversion in III

*Note that sinus tachycardia may be the only abnormality present.*

## Percutaneous coronary intervention

Angioplasty and coronary artery stenting can be used to reopen occluded arteries in acute myocardial infarction instead of thrombolysis. Coronary angiography allows direct visualization of the coronary arterial anatomy. It is used in angina to determine whether elective angioplasty or coronary artery bypass grafting might be beneficial.

## Imaging for pulmonary embolism

Ventilation–perfusion ( $\dot{V}/\dot{Q}$ ) scan was the standard imaging used to diagnose PE. However, interpretation of this test can be difficult, so a CT pulmonary angiogram is now preferred to a  $\dot{V}/\dot{Q}$  scan in many centres, especially if underlying lung disease is present. Pulmonary angiography via cannulation of the pulmonary arteries remains the definitive investigation when there are doubts regarding the diagnosis.

## Exercise test

An exercise test may be diagnostic when angina is suspected. It is mainly used in risk stratification post MI or in the outpatient clinic when investigating chest pain. It is CONTRAINDICATED in acute coronary syndromes.

## Upper gastrointestinal endoscopy

Upper gastrointestinal endoscopy will confirm oesophagitis and should be considered when the cause of chest pain is unclear.

## Chest X-ray

Pneumothorax, consolidation (pneumonia), widened mediastinum (aortic dissection), pulmonary oedema (myocardial ischaemia/infarction) and fractured ribs may be detected on CXR.

## Arterial blood gases

The assessment of arterial blood gases is useful in determining the severity of PE, pneumonia or pulmonary oedema, showing hypoxia and occasionally hypocapnia. In hyperventilation related to anxiety, the  $P_{O_2}$  may be mildly elevated while there will be hypocapnia and a respiratory alkalosis.

## Echocardiogram

Echocardiography can be used acutely to demonstrate cardiac dysfunction, valvular pathology, pericardial effusions and aortic dissection (particularly transoesophageal echocardiography). Computed tomography (CT) is an alternative in aortic dissection.

